

Peritoneal catheter subcutaneous cuff removal – a rescue treatment for exit-site infection refractory to medical treatment

Carla Lima¹, Anabela Rodrigues², Sofia Pedroso², Fernanda Silva², Sandra Silva², António Cabrita²

¹ Nephrology Department, Centro Hospitalar de Coimbra. Coimbra, Portugal.

² Nephrology Department, Hospital Geral de Santo António. Porto, Portugal.

Received for publication: 25/08/2006

Accepted in revised form: 22/12/2006

■ ABSTRACT

Introduction: Access related infections in peritoneal dialysis patients are major causes of drop-out and switch to haemodialysis. Rescue therapies include the external cuff shaving in exit-site infections (ESI).

Objectives: To evaluate the efficacy of the external cuff shaving procedure on refractory ESI and tunnel infections (TI) in our single centre experience.

Patients and Methods: We reviewed data on this procedure covering the last 20 years (1985-2005) of the peritoneal dialysis (PD) programme in our hospital.

Results: During this period, a total of 376 Tenckhoff catheters were implanted and 312 patients were treated. In 34.5% of the patients transferred to haemodialysis the cause was access related infection. Global catheter cumulative survival was 82%, 64% and 50% at 1, 3, and 5 years respectively. A total of 35 subcutaneous cuff excisions were electively performed in 33 patients (one patient had cuff shaving on three different catheters) with ESI unresponsive to medical therapy. Twenty two (66%) had persistent ESI with *Staphylococcus aureus*, four (11%) with *Pseudomonas aeruginosa*, four (8%) with *Serratia*, two (6%) with *Corynebacterium*, one (3%) with *Staphylococcus epidermidis*, one (3%) with *Proteus*

mirabilis and one (3%) with *Escherichia coli*. Five (14%) patients had ESI with associated TI. The time interval between catheter implantation and ESI was 18.4±15.94 months.

The procedure was effective in eliminating the infection and avoided catheter removal in (28) 80% of the cases. It was a safe procedure with a complication rate of only 6% (two catheter rupture). External cuff shaving allowed extending the time of treatment on PD for a further 30±19.8 months, median 26 months.

Conclusions: Cuff shaving procedure is a successful rescue therapy for persistent ESI/TI. It avoids catheter replacement, extending technique survival.

■ Key-Words:

Peritoneal dialysis catheter; exit-site infection; subcutaneous cuff shaving.

■ INTRODUCTION

Peritoneal dialysis (PD) is an efficient chronic renal replacement therapy modality¹. Despite their decreasing rate², the access related infections exit-site infection (ESI) and tunnel infection (TI) are still an important morbidity factor and a significant cause of drop-out, necessitating a temporary or permanent

switch to haemodialysis³. Absence of response to antibiotherapy leads to catheter replacement. In these resistant infections, it is possible to perform shaving of the external cuff of the catheter as the final conservative therapy. References to the effectiveness of this rescue technique are scarce^{4,5}. In order to evaluate the effectiveness of the procedure in refractory ESI and TI in our Unit, we retrospectively studied the clinical records of the patients electively submitted to a shaving of the external cuff procedure in the period between October 1985 and December 2004.

PATIENTS AND METHODS

During the period in question, 376 double-cuff Tenckhoff catheters were implanted in 312 patients treated by PD in our Unit. The Tenckhoff catheters were implanted in the operating room generally by mini-laparotomy⁶. In the last four years the Popovich-Moncrief technique⁷ was used in 77 catheters. In 40 (34.5%) patients the cause of transfer to haemodialysis was access related infection. Global catheter cumulative survival was 82%, 64% and 50% at 1, 3, and 5 years respectively.

Prophylaxis and treatment protocols were followed according to international recommendations^{8,9}, with the main ones briefly summarised in Table I.

Table I

Major ESI prophylactic and treatment procedures

External cuff shaving is performed as an out-patient ambulatory procedure in the PD exchange room under local anaesthesia (lidocaine 1%). A small incision is made at the external exit site towards the external subcutaneous cuff, which is usually easily palpated. When the external cuff is exteriorised it is then removed, literally by shaving, with a bistoury or a shaving blade. Skill is necessary to avoid injuring the silicone catheter. Second intention cutaneous healing is left to occur under antibiotics.

RESULTS

Thirty-five subcutaneous cuff excisions were electively performed in 33 patients (1 patient had cuff shaving on three different catheters) with ESI/TI refractory to conservative management. Patients were 51±13 years old, 18 (51%) male, 27 were on CAPD and 8 were on APD.

The time interval between the implantation of the catheter and the ESI averaged 18.4±15.94 months, median 15.4 months. Five (14%) patients presented associated TI. In 23 cases (65%) the agents of the refractory ESI were Gram-positive germs, mainly methicillin susceptible *Staphylococcus aureus* (60%); *Pseudomonas aeruginosa* occurred in 11% and *Serratia* in the remaining 11% (Table II).

Table II

Aetiologic ESI/TI agents and cure rate after peritoneal catheter external cuff shaving.

ESI/TI Agents	n (%)	Cure rate after cuff shaving
Methicillin susceptible <i>S. aureus</i>	21 (60 %)	18 (86%)
Methicillin resistant <i>S. aureus</i>	1 (3 %)	1 (100%)
<i>S. epidermidis</i>	1 (3 %)	1 (100%)
<i>Pseudomonas aeruginosa</i>	4 (11 %)	3 (75%)
<i>Serratia</i>	4 (11 %)	3 (75%)
<i>Corynebacterium</i>	2 (6 %)	2 (100%)
<i>P. mirabilis</i>	1 (3 %)	0 (0%)
<i>E. coli</i>	1 (3 %)	0 (0%)

Cuff shaving was effective in eliminating the infection in 28 episodes. In the remaining 7 episodes infection persisted and the catheter was removed.

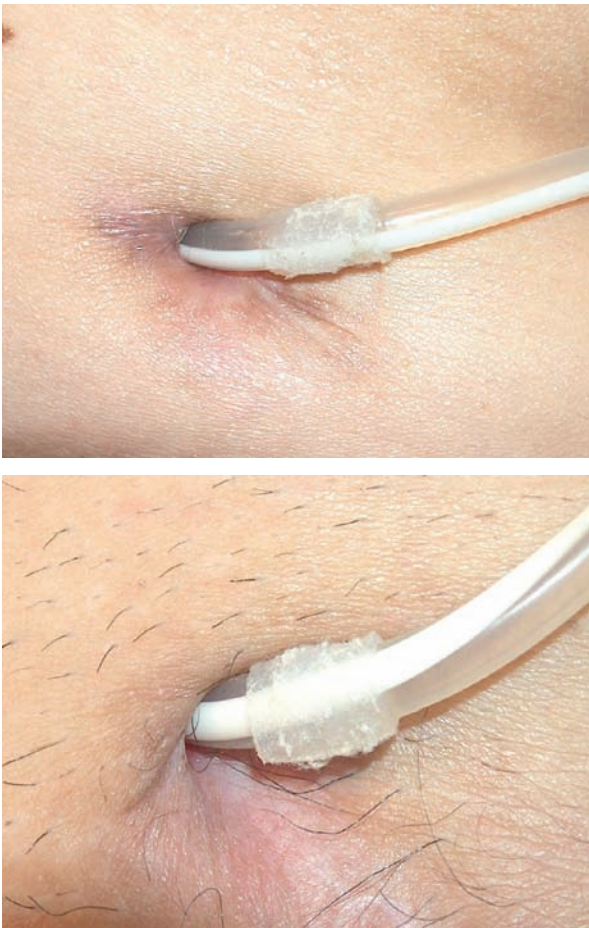


Figure 1
Common aspect of the exit orifice after successful shaving.

Cuff shaving successfully treated 87% of Gram+ infections and 67% of Gram– infections. Figure 1 shows the common aspect of the exit orifice after successful shaving.

During the shaving procedure accidental ruptures occurred in 2 catheters, corresponding to a 6% complications rate. It necessitated the urgent revision of the catheter with a new catheter extension kit repair.

The follow-up after successful shaving cases documented the need for subsequent catheter removal in 3 patients: 1 due to exteriorisation of internal cuff (6 months after the procedure), 1 due to delayed catheter rupture (13 months after shaving), and 1 due to a new refractory (25.7 months after the proce-

dure). Of the remaining 25 patients, 4 are still on PD without any further ESI. Twenty-one discontinued the technique for reasons not related to the access. Shaving allowed extending the time of treatment on PD for a further 30 ± 19.8 months.

■ DISCUSSION

There are very few publications on the effectiveness of peritoneal catheter subcutaneous cuff removal as a rescue treatment for exit-site infection refractory to medical treatment. Despite this scarcity the technique has been carried out in some centres with good results, allowing the extension of PD technique.

The first description of the procedure was published by Nichols and Nolph in 1983, but its effectiveness was not reported. Since then, more recent studies¹⁰⁻¹³ have described success rates of 49-88%, with significantly better results in the ESI caused by Gram-positive germs. A comparative study carried out in a paediatric population concluded that shaving allowed saving the catheter and was as efficient as replacing the catheter, when the number and time interval of new infections were taken into account¹⁴.

In our study, the procedure eliminated the infection in 80% of the cases, also with significantly superior results in the Gram-positive infections; 87% cured versus 67% of Gram-negative infections.

Our experience demonstrates that the procedure can be successfully carried out with low risk on an out-patient basis. It is obviously less invasive than catheter replacement, even if the peritoneoscopic method is chosen. It is also less of a psychological burden for the patient.

As with any procedure, the operator experience and skill matters, since there is always a danger of accidental catheter lesion.

Timely intervention with cuff extrusion also might avoid extended antibiotic therapy which brings with it the risk of fungal peritonitis, a severe and life threatening complication which can occur after prolonged antibiotic treatment¹⁵.

■ CONCLUSIONS

We conclude that cuff shaving procedure is a successful rescue therapy for persistent ESI/TI, especially those due to Gram-positive organisms. It reduces morbidity and avoids catheter replacement, extending technique survival.

Conflict of interest statement. None declared.

References

- 1 Blake PG. Integrated end-stage renal disease care: the role of peritoneal dialysis. *Nephrol Dial Transplant* 2001;16 (suppl 5):S61-S66.
- 2 Whaley-Connell A, Pavey BS, Satalowich R, *et al*. Rates of continuous ambulatory peritoneal dialysis-associated peritonitis at the University of Missouri. *Adv Perit Dial* 2005;21:72-75.
- 3 Piraino B, Bernardini J, Sorkin M. Catheter infections as a factor in the transfer of continuous ambulatory peritoneal dialysis patients to hemodialysis. *Am J Kidney Dis* 1989;13:365-369.
- 4 Gloor HJ, Nichols WK, Sorkin MI, *et al*. Peritoneal access and related complications in continuous ambulatory peritoneal dialysis. *Am J Med* 1983;74:593-598.
- 5 ISPD Guidelines/Recommendations. *Peritoneal Dialysis International* 2005;25:107-131.
- 6 Ash SR. Chronic peritoneal dialysis catheters: procedure for placement, maintenance, and removal. *Semin Nephrol* 2002;22:221-236.
- 7 Danielsson A, Blohme L, Traanaeus A, Hylander B. A prospective randomized study of the effect of a subcutaneously "buried" peritoneal dialysis catheter technique versus standard technique on the incidence of peritonitis and exit-site infection. *Perit Dial Int* 2002;22:211-219.
- 8 Piraino B, Bailie GR, Bernardini J, *et al*. Peritoneal dialysis-related infections recommendations: 2005 update. *Perit Dial Int* 2005;25:107-131.
- 9 Piraino B. Peritoneal dialysis infections recommendations. *Contrib Nephrol* 2006;150:181-186.
- 10 Scalamogna A, De Vecchi A, Maccario M, Castelnovo C, Ponticelli C. Cuff shaving procedure. A rescue treatment for exit-site infection unresponsive to medical therapy. *Nephrol Dial Transplant* 1995;10:2325-2327.
- 11 Suh H, Wadhwa N, Cabralda T, Bonanno J, Wasiluk A, Sorrento J. Persistent exit-site/tunnel infection and subcutaneous cuff removal in PD patients. *Adv Perit Dial* 1997;13:233-236.
- 12 Suh H, Wadhwa N, Cabralda T. Subcutaneous cuff removal in persistent exit-site/tunnel infections in peritoneal dialysis. *Adv Perit Dial* 1995;11:157-159.
- 13 Scalamogna A, Castelnovo C, De Vecchi A, Ponticelli C. Exit-site and tunnel infections in continuous ambulatory peritoneal dialysis patients. *Am J Kidney Dis* 1991; 18:674-677.
- 14 Yoshino A, Honda M, Ikeda M, *et al*. Merit of the cuff-shaving procedure in children with tunnel infection. *Pediatric Nephrol* 2004;19:1267-1272.
- 15 Prasad N, Gupta A. Fungal peritonitis in peritoneal dialysis patients. *Perit Dial Int* 2005;25:207-222.

Correspondence to:

Dr Carla Lima
Rua Afrânio Peixoto, 40 - 3^o B
3000-013 Coimbra, Portugal
cmplima@gmail.com