

Tuberculous peritonitis in a kidney transplant patient: a difficult diagnosis

Flora Rico Sofia, Helena Sá, Luís Freitas, Henrique Gomes, Mário Campos

Serviço de Nefrologia. Hospitais da Universidade de Coimbra. Coimbra, Portugal.

Received for publication: 04/04/2007

Accepted in revised form: 28/08/2007

■ ABSTRACT

The authors present the case of a 52 year-old male patient, diabetic, kidney transplant recipient admitted to hospital for ascites, abdominal pain, sub-febrile temperatures, weight loss, asthenia and anorexia. After one month with no diagnosis, patient developed multiple cervical and submandibular adenopathies, one of which was surgically removed. The histopathology of the incised cervical node was very suggestive of tuberculosis. Antibacillary therapy was started, leading to involution of ascites and reduction of the size of the adenopathies. Two years following the diagnosis of peritoneal and ganglionic tuberculosis, the patient had no symptoms and no recurrence, confirming the clinical diagnosis.

This patient presented with the majority of the risk factors for peritoneal tuberculosis: immunosuppression, end-stage renal failure, diabetes mellitus, history of tuberculous exposure, a history of alcoholism and chronic liver disease.

Tuberculous peritonitis with ascites is a common presentation in haemodialysis patients but uncommon in renal transplant patients. This patient had chronic kidney dysfunction and resumed haemodialysis during hospital admission.

When a patient presents with abdominal pain, fever and weight loss persisting more than a few weeks, tuberculous peritonitis must be considered in the differential diagnosis. The authors present this

case to highlight the difficulty of establishing the correct diagnosis and review the principal factors of early diagnosis and treatment.

The tuberculin test, the PA chest film, the sputum, pleural fluid and ascites fluid direct smear for Ziehl-Neelsen stain and culture for *Mycobacterium tuberculosis* have low sensitivity and low specificity in the diagnosis of tuberculosis. Better and faster diagnostic tests (PCR of ascites fluid for *Mycobacterium tuberculosis* and laparoscopy with directed peritoneal biopsy) are warranted in reducing mortality from this infection, since treatment delay has been proven to be the most significant peritoneal tuberculosis mortality factor.

Key-Words:

Immunosuppression; kidney transplant; peritoneal tuberculosis.

■ INTRODUCTION

One half of the world's population is infected with *Mycobacterium tuberculosis*, and it is the leading cause of infectious death, with approximately 2 million deaths annually¹⁻⁵. The reported frequency of infection by *Mycobacterium tuberculosis* in the transplant population ranges from 0.2% to 15% (mean frequency 3.7%), which is 6-62 (mean 26) times the incidence in the general population. Geographic differences may

influence this wide range⁴⁻¹⁰. In Portugal the incidence of tuberculosis in the general population is 33.7 per 100,000¹¹.

The risk of tuberculosis is greatest during the first months post-transplant, when immunosuppression is maximal, but it has been diagnosed at any time after transplantation⁴. Gastrointestinal tuberculosis is defined as Mycobacterium tuberculosis organisms infection of the peritoneum, hollow or solid abdominal organs and abdominal lymphatics. The peritoneum and the ileocecal region are the most likely sites of infection and are involved in the majority of cases by haematogenous spread or through swallowing of infected sputum from primary pulmonary tuberculosis^{6,12,13}.

In the public at large, the most common presentation is pleuropulmonary tuberculosis. Gastrointestinal tuberculosis is the sixth most common extrapulmonary location, following lymphatic, genitourinary, bone and joint, miliary and meningeal tuberculosis¹³. While the most common presentation in renal transplant recipients is also pleuropulmonary tuberculosis, extrapulmonary involvement is more common than in the general population^{4,7,8,10,14}.

In the general public, the most frequent clinical characteristics of patients with peritoneal tuberculosis are abdominal pain, ascites and fever. Nausea, vomiting, diarrhoea and constitutional symptoms may also be present^{1-3,13}. Renal transplant recipients may present with abdominal pain, fever, constitutional symptoms and night sweats^{4,7-10}.

Diagnosis is often difficult because the patients are immunocompromised, have non-specific signs and symptoms and frequently present atypical manifestations^{2,3,6,8-10,15}.

■ CASE REPORT

The authors present the case of a 52 year-old male kidney transplant recipient who was admitted to hospital in September 2004, complaining of distended abdomen, sub-febrile temperatures (intermittent pattern), weight loss of 5 Kg over 5 months, asthenia and anorexia. He denied having nocturnal sudoresis, cough, expectoration and breathing problems.

The physical examination showed a patient who was conscious, collaborative and orientated regarding time and place. His BP was 160-90 mmHg and pulmonary auscultation revealed symmetric vesicular murmur audible bilaterally. He presented bibasal inspiratory rales. The laboratory tests revealed. Hb 13.4 g/dl; Leucocytes 5.5 G/L; Platelets 157 G/L; Serum creatinine 4.5 mg/dl; BUN 115 mg/dl; Albumin 3.1 g/dl; Total protein 5.0 g/dl; GGT 90 U/L; TGO 16 U/L; TGP 20 U/L; LDH 132 U/L; Alkaline phosphatase 219 U/L; Total bilirubin 0.6 mg/dl; C-reactive protein 0.4 mg/dl.

Abdominal and renal ultrasonography was performed and showed bulky ascites peritoneal fluid in all abdominal areas. Maintenance immunosuppression was initiated with cyclosporine 175 mg id, mycophenolate mophetil 1g id and prednisolone 2.5 mg id. The patient was admitted to the Nephrology Unit diagnosed with ascites of unknown cause and terminal chronic dysfunction of the transplanted kidney.

The patient's historical background was chronic kidney failure, aetiology unknown. The patient underwent haemodialysis treatment for two years before the transplant, receiving a kidney from a cadaver donor in November 1992. Main comorbidities were pneumopathy of the right lung at the age of 26, probably due to tuberculosis, for which he was treated accordingly. He also presented chronic venous insufficiency of the lower limbs and high blood pressure was diagnosed at the age of 30. Patient had had marked ethylic habits up until 12 years ago, remaining in abstinence since then. He had positive hepatitis C virus antibodies; serology negative for AgHBs, HIV 1 and 2. He had light chronic hepatitis with portal fibrosis. In February 1993 he was diagnosed with diabetes mellitus requiring insulin therapy. In April 1997, azathioprine was withdrawn due to occasional increases of the transaminase levels with normal kidney function and mycophenolate mophetil was prescribed in September 2000. The patient had chronic renal allograft nephropathy (Grade II, Banff 97). Kidney biopsy was performed in June 2004.

In terms of occupational history, the patient worked for six years in a brick factory, two years in a cement factory and thirteen years in civil construction; all dusty environments, without using a mask. He was a non-smoker, and his family background is irrelevant to this study.

After admittance to the Nephrology Unit, he began a regular haemodialysis programme, which he maintains at the present time. Accessory tests were carried out, from which we emphasise the following. Diagnostic and evacuatory paracentesis (3 litres) – cytological study: Total cells: 700/mm³; neutrophils: 6%; eosinophils: 0%; lymphocytes: 41%; monocytes and macrophages: 0%; other cells: 53%. Blood smear, small lymphocytes and other reactive mesothelial cells; absence of neoplastic cells. Biochemical study: Transudate. Glucose: 254 mg/dl; albumin: 1.7 g/dl; total proteins: 2.6; LDH: 97; pH: 7.49; ADA: 20.3 (ADA <40 UI/L: neoplasty. ADA >40 UI/L: tuberculosis). Microbiological study: Negative direct examination for mycobacteria. Negative culture for bacteria and mycobacteria.

Two paracentesis were subsequently carried out, presenting identical results. The tuberculin test was negative and there were normal tumour markers. High digestive endoscopy and colonoscopy were performed and did not reveal any abnormalities. An abdominal and pelvic CAT scan were undertaken and showed free bulky peritoneal effusion and bilateral pleural thickening. There were no other relevant alterations detected.

High resolution CAT scan of the thorax revealed emphysematous alterations and residual fibrotic grooves in the right upper lobe, a non-calcified nodule in the apical segment of the left lower lobe with well-defined contours, 1.5 cm long, prolonged by a band opacity with a residual aspect.

An optical bronchofibroscopy was undertaken, and did not show any relevant alterations. A polymicrobial culture was taken, with direct examination and culture for mycobacteria negative. Cytomegalovirus research was also negative, with the cytology of the brushed and aspirated bronchial not detecting neoplastic cells.

Multiple painful cervical and submandibular adenopathies appeared, one month after admission to hospital. One of the adenopathies was removed and its histopathological test revealed epithelioid granulomas with giant Langhans cells and central incomplete necrosis, surrounded by a palisade of histiocytary cells – Ziehl-Neelsen negative. (Fig. 1 and 2)

The patient started antibacillary therapy, which was followed by a rapid reduction of the ascites volume

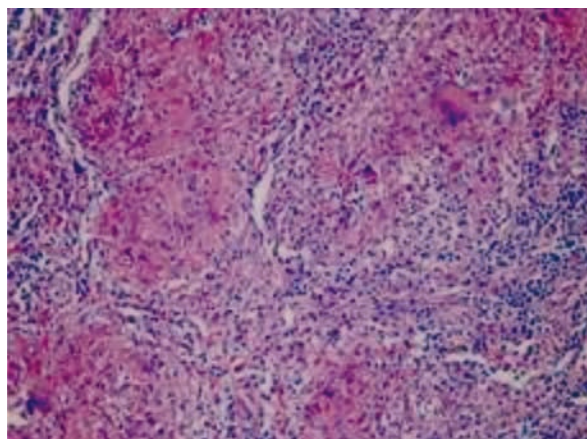


Figure 1

Cervical node. Epithelioid granulomas with giant Langhans cells (Haematoxylin-Eosin x 200)

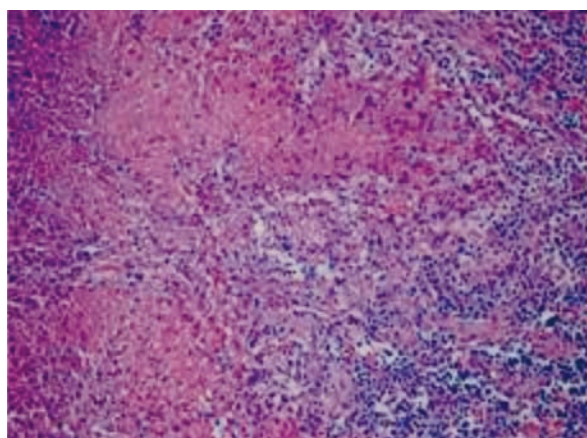


Figure 2

Cervical node. Granulomas with central incomplete necrosis (Haematoxylin- Eosin x 400)

and the size of the adenopathies. The therapeutic regimen was isoniazid 300 mg id, rifampicin 600 mg id, pyrazinamide 1000 mg id and pyridoxine id for 2 months and isoniazid 300 mg id and rifampicin 600 mg id, up to one year.

The patient was discharged and referred to the Pulmunology Disease Centre. Two years after the diagnosis of peritoneal and ganglionic tuberculosis, the patient was asymptomatic and there was no recurrence of disease.

■ DISCUSSION

Diagnosis is often difficult because the patients are immunocompromised, have non-specific signs and symptoms and frequently show atypical manifestations^{2,3,6,8-10,15}. This patient presented with the majority of the risk factors for peritoneal tuberculosis: immunosuppression, end-stage renal failure, diabetes mellitus, a history of alcoholism and chronic liver disease^{1,4,6,14,16}.

The tuberculin test was negative due to immunological impairment secondary to immunosuppression. In this setting, a negative PPD is not an accurate diagnostic tool for tuberculosis¹⁷.

Paracentesis gives low diagnostic yield. Direct smear for Ziehl-Neelsen stain is unhelpful most of the time with reported sensitivity ranging from 0% to 6%. Culture of ascitic fluid takes considerable time before results are available and negative results occur in the majority of tuberculous ascites^{2,18,19}. Culture positivity rate is 20-83%³ and the culture positive rate could be improved by obtaining 1 litre of ascitic fluid concentrated by centrifuging¹.

The measurement of ascites adenosine deaminase (ADA) levels represents a diagnostic advance in tuberculous peritonitis, particularly in underdeveloped areas where the disease is common and laparoscopy may not be available, or in risk groups coming from endemic areas^{2,19}.

ADA is an enzyme involved in the proliferation and differentiation of lymphocytes and is expected to increase during the cellular immune response to *Mycobacterium tuberculosis*¹; ADA (ascitic fluid) > 40 UI/L. This patient's ADA (ascitic fluid) was 20.3 UI/L (negative response due to immunosuppression). ADA > 32.3 UI/L has a sensitivity of 100% and specificity of 96% in the diagnosis of peritoneal tuberculosis^{2,8,13}.

In one series, PCR of ascitic fluid was positive for *Mycobacterium tuberculosis* in all cases¹⁸. PCR of ascitic fluid was not available in our hospital. Laparoscopy with directed biopsy currently is the best way to make a rapid specific diagnosis (sensitivity 85 to 100%) and has a low complication rate^{1-3,13,18}. For a definitive diagnosis of tuberculous peritonitis, microbiological and/or histological confirmation is indicated.

The histopathology of the cervical node was very suggestive of tuberculosis but in order to establish the definitive diagnosis, direct smear for Ziehl-Neelsen stain would have to be positive, although direct smear for Ziehl-Neelsen stain is frequently negative in ganglionic tuberculosis.

In countries with considerable prevalence of peritoneal tuberculosis, a therapeutic trial of antituberculous drugs may be reasonable if the clinical picture is compatible^{6,19}. Diagnosis of peritoneal tuberculosis can be confirmed if the patient responds to treatment and this is followed by no recurrence^{1,2,9}.

The response to the antibacillary therapy with involution of ascites and reduction of the size of the adenopathies (2 years after the diagnosis of peritoneal and ganglionic tuberculosis the patient had no symptoms and no recurrence) confirms the diagnosis of peritoneal and ganglionic tuberculosis.

Peritoneal tuberculosis is a growing health concern worldwide. Identification of infected persons requires a high index of suspicion. Therapy is highly effective. More importantly, better diagnosis is warranted in reducing the disease mortality from this infection, since treatment delay has been proven to be the leading tuberculous peritonitis mortality factor^{1,2,4,8,9,13,20}.

Conflict of interest statement. None declared.

References

- 1 Chow KM, Chow VC, Szeto CC. Indication for peritoneal biopsy in tuberculous peritonitis. *Am J Surg* 2003;185:567-573
- 2 Marshall JB. Tuberculosis of the gastrointestinal tract and peritoneum. *Am J Gastroenterol* 1993;88:989-999
- 3 Bernhard JS, Joy S, Bhatia G, Knauer CM. Gastrointestinal tuberculosis: An eighteen-patient experience and review. *J Clin Gastroenterol* 2000;30:397-402
- 4 Chen C-H, Lian J-D, Cheng J-D, Wu M-J, Lee W-C, Shu K-H. *Mycobacterium tuberculosis* infection following renal transplantation in Taiwan. *Transpl Infect Dis* 2006;8:148-156
- 5 Jie T, Matas AJ, Gillingham KJ, Sutherland DER, Dunn DL, Humar A. Mycobacterial infections after kidney transplant. *Transplant Proc* 2005;37:937-939
- 6 Vachharajani T, Abreo K, Phadke A, Oza U, Kirpalani A. Diagnosis and treatment of tuberculosis in hemodialysis and renal transplant recipients. *Am J Nephrol* 2000;20:273-277
- 7 Aguado J, Herrero JA, Gavalda J, *et al*. Clinical presentation and outcome of tuberculosis in kidney, liver, and heart transplantation recipients in Spain. *Transplantation* 1997;63:1278-1286

- 8** Queipo JA, Broseta E, Santos M, Sánchez-Plumed J, Budía A, Jiménez-Cruz F. Mycobacterial infection in a series of 1261 renal transplant recipients. *Clin Microbiol Infect* 2003;9:518-525
- 9** Niewczas M, Ziolkowski J, Rancewicz Z. Tuberculosis in patients after renal transplantation remains still a clinical problem. *Transplant Proc* 2002;34:677-679
- 10** Dridi A, Kaaroud H, Boubaker K. Tuberculosis in renal transplant recipients. *Transplant Proc* 2003;35:2682-2683
- 11** Direcção Geral da Saúde, Divisão de Doenças Transmissíveis. Programa Nacional de Luta Contra a Tuberculose. Março de 2005.
- 12** Sheer TA, Coyle WJ. Gastrointestinal tuberculosis. *Curr Gastroenterol Rep* 2003;5:273-278
- 13** Lisehora GB, Peters CC, Lee YTM, Barcia PJ. Tuberculous peritonitis - do not miss it. *Dis Colon Rectum* 1996;39:394-399
- 14** Ergun I, Ekmekci Y, Sengul S. Mycobacterium tuberculosis infection in renal transplant recipients. *Transplant Proc* 2006;38:1344-1345
- 15** Klote MM, Agodoa LY, Abbott K. Mycobacterium tuberculosis infection incidence in hospitalized renal transplant patients in the United States, 1998-2000. *Am J Transplant* 2004;4:1523-1528
- 16** John G T, Shankar V, Abraham AM, Mukundan U, Thomas PP, Jacob CK. Risk factors for post-transplant tuberculosis. *Kidney Int* 2001;60:1148-1153
- 17** Lattes R, Radisic M, Rial M, Argento J, Casadei D. *Transpl Infect Dis* 1999;1:98-104
- 18** Uzunkoy A, Harna M, Harna M. Diagnosis of abdominal tuberculosis: Experience from 11 cases and review of the literature. *World J Gastroenterol* 2004;10:3647-3649
- 19** Gimenez AR, Xiol X, Castellote J. The value of ADA in peritoneal tuberculosis. *Rev Esp Enf Digest* 1992;82:32-34
- 20** Danovitch G. M., *Handbook of Kidney Transplantation*; 3rd ed. Philadelphia: Lippincott Williams and Wilkins, 2001; 10

Correspondence to:

Dr Flora Rico Sofia
 Department of Nephrology
 Hospitais da Universidade de Coimbra.
 Praceta Mota Pinto, 3030 Coimbra, Portugal
 e-mail: fmdrs@iol.pt