

Heparin-induced thrombocytopenia in a haemodialysis patient: use of Lepirudin

Elena González, Teresa Olea, Jorge Martínez Ara, Covadonga Hevia, José Luís Miguel, Alberto Torre, Carmen González, Rafael Selgas

Department of Nephrology, Hospital Universitario La Paz. Madrid, Spain.

Received for publication: 06/06/2007

Accepted in revised form: 27/09/2007

■ ABSTRACT

Heparin-induced thrombocytopenia is an infrequent but serious complication in haemodialysis patients. It is characterised by the presence of thrombocytopenia after the administration of unfractionated and low-molecular-weight heparin and sometimes thrombotic manifestations. Its treatment consists of the withdrawal of all heparin sources and reducing the risk of thrombosis.

Lepirudin is a recombinant analogous hirudin that binds in an irreversible and direct manner to the thrombin, and could be used as an extracorporeal circuit anticoagulant.

We present the case of a chronic haemodialysis patient who presented this complication, and the treatment with Lepirudin.

Key-Words:

Heparin-induced thrombocytopenia; HIT type II; haemodialysis; Lepirudin.

■ INTRODUCTION

Heparin is the anticoagulant most frequently used to prevent thrombosis of the extracorporeal circuit in haemodialysis. While thrombocytopenia induced by heparin (HIT) type II is one of the more serious

complications of heparin treatment, it is infrequent in haemodialysis patients, in spite of this population being overexposed to this drug. It is characterised by the existence of thrombocytopenia and paradoxical hyper-coagulability, with thrombotic manifestations.

We present the case of a haemodialysis patient who presented this complication, and the treatment.

■ CASE REPORT

Our patient was an 80 year-old male with a history of gastro-intestinal haemorrhage secondary to a bleeding duodenal ulcer. He had perforation of a post-pyloric duodenal ulcer in August 2003 that required surgical repair. He also had Mallory Weiss syndrome. His chronic renal disease was secondary to a focal segmental glomerulosclerosis for hyper-leak and a left nephrectomy for renal tuberculosis.

In October 2005 he presented at the emergency room with a medical profile of marked asthenia, melae-nas and hypotension, clinically compatible with a gastro-intestinal haemorrhage. He was transfused with 6 units of red packed cells and underwent a gastroscopy, which detected no bleeding point. He was prescribed gastric protection, presented no further episodes of bleeding, and remained clinical and analytically stable.

Deterioration of the renal function (creatinine 7.9 mg/dl and urea 396 mg/dl) was also detected, improving with serotherapy until its basal value. Nevertheless, as the patient presented a creatinine clearance of 10ml/min and uraemic symptoms, he initiated haemodialysis via a right internal jugular Permcath, using sodium heparin as the extracorporeal circuit anticoagulant.

Ten days into haemodialysis, the patient presented reddening and oedema of the right leg, with proximal deep venous thrombosis diagnosed by echo-doppler, for which he initiated treatment with low-molecular-weight heparin (LMWH). Three days later, an acute thrombopenia was detected (number of platelets dropping from 108000 to 44000/mm³). As a possible HIT was suspected, the LMWH treatment was suspended. No new episodes of thrombosis were detected. Thrombopenia recovered progressively and reached a normal value within a week of LMWH suspension (154000 platelets/mm³) (Fig. 1). The determination of antibodies against the heparin-platelet factor 4 (PF₄) complex was carried out using an ELISA test (GTI PF₄) to establish diagnosis. This was positive (3395; positive control 2.68, negative 0.17).

Due to the high risk of bleeding, the thrombocytopenia and the patient's age, it was decided not initiate treatment with oral anticoagulants and to place a filter in the lower vein cave to minimise the risk of a pulmonary thromboembolism.

Haemodialysis was carried out without anti-coagulation, with normal saline priming of the extracorporeal circuit and urokinase locks for dialysis catheter. In spite of this, the patient presented numerous

episodes of clotting of the extracorporeal circuit, making daily haemodialysis necessary. Hence, we initiated lepirudin (Refludin[®]) 0.05 mg/kg (3 mg in total) as circuit anti-coagulant at the beginning of each dialysis session, in addition to saline priming of the circuit and 0.4 cc of lepirudin in each lumen of the catheter. Lepirudin was increased progressively according to clinical needs, reaching 0.2 mg/kg dose (13 mg session) after two months. Under this regimen, the patient has not presented any episode of thrombosis of the extracorporeal circuit. Citra-lock[®] is used as catheter lock.

DISCUSSION

HIT is a serious pathology, produced by exposure to unfractionated heparin (UFH) or, 10 times less frequently, to LMWH^{1,2}. It is characterised by a drop in the number of platelets (less than 100,000 platelets/mm³ or with a relative descent greater than 50% of the basal value) and by the simultaneous development of thrombosis in 25-50 % of the cases^{3,4}. In our case, the patient's platelets dropped to 44000/mm³, climbing back up again completely after suspending LMWH and UFH from the haemodialysis sessions, with no evidence of new episodes of thrombosis.

This clinical picture is more usual among surgical patients, particularly orthopaedic surgery. HIT is an infrequent pathology among paediatric patients, obstetric patients and those on chronic haemodialysis. It is more prevalent in acute than chronic dialysis patients.

Two clinical pictures^{1,2,5} (Table I) are recognised:

- HIT type I is a benign form, without immune mediation. It seems to be related to the direct action of heparin over the aggregation of platelets and the thrombopenia is usually moderate (<50 %). It is reversible, has no clinical significance and often resolves spontaneously.
- HIT type II appears 5-10 days after heparin exposure, unless there was prior exposure to heparin in the previous 100 days, in which case it can appear before this timeframe. Thrombocytopenia is moderately severe, resolving within a week

Number of platelets/mm³

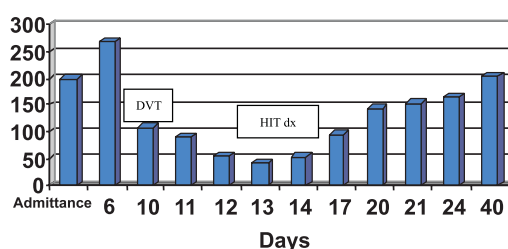


Figure 1

Evolution of the number of platelets during hospital stay

Table I

Clinical picture of heparin-induced thrombocytopenia

	HIT type I	HIT type II
Incidence	5-10 %	0-3 %
Onset	2-3 days after UFH exposure	5-12 days after UFH exposure
Platelet count	Decrease of the number of platelets to 50 % of basal value.	Decrease to 100,000 or a drop greater than 50 % of its basal value
Complications	None	Thromboembolism
Treatment	None	1. Heparin suspension 2. Direct thrombin inhibitors or heparinoids 3. Dicumarinics

of heparin suspension, as occurred in our case, and there is a greater tendency to thrombosis. Other atypical forms of presentation are allergic systemic reactions, acute respiratory distress, transient global amnesia and even sudden cardiorespiratory arrest.

HIT type II pathogenesis is related to the formation of IgM, IgG or IgA antibodies which recognise an epitope on the heparin-platelet factor 4 (PF₄) complex. This complex binds to receptors on the platelet surface and cross-links the receptors, resulting in platelet activation and aggregation, further release of PF₄ and the simultaneous formation of procoagulant, platelet-derived microparticles and thrombin.

HIT type II diagnosis is mainly clinical in patients who present thrombocytopenia after heparin administration (when other causes such as drugs, infections, etc. have been ruled out), and the situation resolves completely with heparin suspension.

Diagnosis can then be confirmed using a heparin-antibody assay. The tests for HIT antibodies are either functional or immunoassays^{6,7}. Heparin-induced thrombocytopenia antibodies result in strong platelet activation, which in turn induces a cascade of events and platelet aggregation, which are detected in functional tests for HIT antibodies detection. Serotonin release assay is considered the gold standard, but it is time consuming and only performed in specialised laboratories. This test is very specific but a negative test does not necessarily exclude the diagnosis. Immunoassays are technically easier and more sensitive, although they give rise to more false-positive results.

In our case, the diagnosis was clinical (severe thrombocytopenia of 44000/mm³ ten days after the start of LMWH treatment in a patient who had just initiated haemodialysis, and therefore, had been exposed to UFH), confirmed by the detection of antibodies in blood (Heparin/PF₄).

The main aim of this treatment is to reduce the risk of thrombosis. The first step must consist of suspending all heparin sources, not only UFH but also LMWH, including the catheters' lock^{1-3,5}. Likewise, treatment with dicumarines is not indicated until after complete resolution of thrombocytopenia, due to risk of necrosis and of gangrene in extremities. In our case, treatment with dicumarines was ruled out due to the patient's history of bleeding, his age and the high risk of re-bleeding.

The second step must consist of the use of anti-coagulant agents, not only direct thrombin inhibitors but also heparinoids, if no contraindications exist (Table II).

Table II

Treatment options for HIT in haemodialysis

Treatment of HIT in dialysis
UFH or LMWH use completely ruled out:
Without anti-coagulation (saline priming)
Regional anti-coagulation with Citrate
Heparinoid of LMH (Danaparoid)
Direct thrombin inhibitors:
Bivalirudin
Lepirudin
Argatroban

There are currently three direct thrombin inhibitors for HIT treatment: Lepirudin, Argatroban and Bivlirudin. These products bind directly to the thrombin and inactivate it. All of them have a short half life and do not have a crossed reaction with heparin (Table III). The anticoagulants available for treating patients with HIT change from country to country.

In our case, Lepirudin was used as the dialysis extracorporeal circuit anticoagulant. Lepirudin is a recombinant hirudin analogue that binds in an irreversible and direct manner to the thrombin. Its route of administration is intravenous and its elimination

Table III

Principal clinical characteristics of the direct thrombin inhibitors and danaparoids

	Danaparoids	Lepirudin	Argatroban	Bivalirudin
Agent type	Anti-factor Xa	Direct thrombin inhibitor	Direct thrombin inhibitor	Direct thrombin inhibitor
Elimination	Renal	Renal	Hepatic	Enzymatic (80%) and renal
Dose in dialysis	3000-3750 U to the start of the dialysis.	One dose of 0.08 mg/kg at start of dialysis.	Bolus of 2-3 g/kg/min at start followed by a continuous infusion of 2 µg/kg/min.	-
Dialysable	-	Yes	No	Yes
Monitoring	Not required. If needed, specific anti-Xa levels can be used.	aPTT 2 hours after the start of treatment. Therapeutic range 1.5-2.5 of the basal value (< 65 seg.).	aPTT 2 hours after the start of treatment. Therapeutic range 1.5-3 of the basal value (< 100sg).	Time of haemorrhage 5 minutes after bolus.
Adverse effects	Bleeding (8%)	Bleeding (17%)	Bleeding (6%)	Bleeding (3%)
Observations	Crossed reaction with the Ab PF4 Heparin in 3.2% of the cases		Unavailable in Europe	Scarce available data.

is renal. The initial recommended dose is 0.08 mg/kg. It must be used with caution in patients with creatinine clearance lower than 15 ml/min, monitoring time of partial activation of the thromboplastin (aPTT) values and adjusting the dose according to clinical needs. No antidote exists, although it is dialysable.

Lepirudin may cause allergic reactions including anaphylaxis, mainly in patients re-exposed to Lepirudin in a second or subsequent treatment course. The risk of anaphylaxis has been estimated to be 0.015% at first exposure and 0.16% after re-exposure to Lepirudin.

Treatment with Lepirudin should be undertaken only in settings where medical assistance is readily available⁸.

In our patient, treatment with Lepirudin (Refludin[®]) was initiated at a dose of 0.05 mg/kg in a bolus at

the start of the dialysis, and was increased during a period of eight weeks to reach the 0.2 mg/kg at which it currently stands. The patient has not presented any episode of bleeding, allergic reaction or anaphylaxis in a period of 18 months and aPTT values remained within range (between 1.5 and 2 times the basal value) (Fig. 2).

The currently available anticoagulants for HIT treatment are more expensive than UFH and LMWH and usually have an increased risk of haemorrhage in renal patients⁹.

It is a common doubt when patients can be safely re-exposed to heparins. There are some reports suggesting that majority of the patients, their antibodies could be transient. However, further studies are required to determine if it is safe to re-introduce LMWH when functional assays are negative although ELISA tests remain positive^{10,11}.

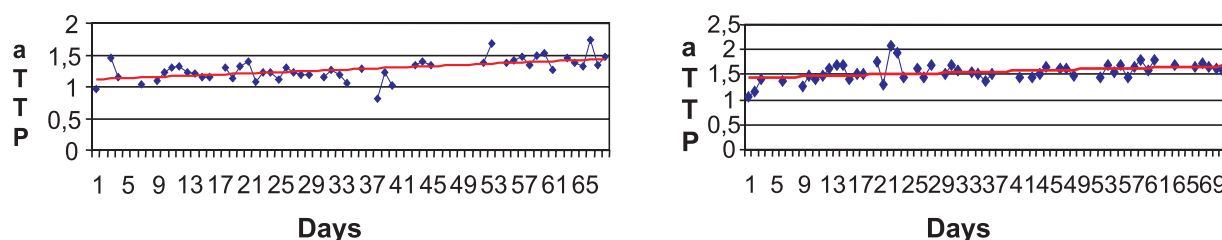


Figure 2

aPTT values pre and postdialysis during clinical evolution (days)

In conclusion, it is worth underlining that HIT type II is a rare entity among dialysis patients, but very serious. At the slightest clinical suspicion, treatment with heparin must be stopped without waiting for confirmation of the diagnosis, to avoid any potentially lethal complications. Lepirudin, when given correctly, is a safe treatment for preventing thrombosis of the dialysis circuit in patients with HIT type II.

Conflict of interest statement. None declared.

References

- 1 Arepally GM, Ortel TL. Heparin-induced thrombocytopenia. *N Engl J Med* 2006;355:809-17
- 2 Daneschvar HL, Daw H. Heparin-induced thrombocytopenia. *Int J Clin Pract* 2007;61:130-137
- 3 Chang JJ, Parikh CR. When heparin causes thrombosis: Significance, recognition and management of heparin induced thrombocytopenia in dialysis patients. *Semin Dial* 2006;19:297-304
- 4 Davenport A. Heparin-induced thrombocytopenia renal during replacement therapy. *Haemodial Inter* 2004;8:295-303
- 5 Charif R, Davenport A. Heparin-induced thrombocytopenia: an uncommon but serious complication of heparin use in renal replacement therapy. *Haemodial Inter* 2006; 10:235-240
- 6 Greinacher A, Warkentin TE. Recognition, treatment, and prevention of heparin-induced thrombocytopenia: review and update. *Thrombosis Research* 2006;118:165-176
- 7 Warkentin TE. Heparin-induced thrombocytopenia: Diagnosis and management. *Circulation* 2004;110:454-458
- 8 Cardenas G, Deiteher S. Risk of anaphylaxis after re-exposure to intravenous Lepirudin in patients with current or past heparin-induced thrombocytopenia. *Mayo Clin Proc* 2005;80:491-93
- 9 Davenport A. HIT on dialysis – when is it safe to re-challenge? *Nephron Clin Pract* 2006;104: 149-150
- 10 Hartman V, Malbrain M, Daelemens R, Meersman P, Zachee P. Pseudo-pulmonary embolism as a sign of acute heparin-induced thrombocytopenia in haemodialysis patients: Safety of resuming Lepirudin after disappearance of HIT antibodies. *Nephron Clin Pract* 2006;104:143-148
- 11 Warkentin TE, Greinacher A. Heparin-induced thrombocytopenia: Recognition, treatment and prevention: The 7th ACCP conference on antithrombotic and thrombolytic therapy. *Chest* 2004;126: 3115-3375

Correspondence to:

Dr Elena González García.
 Servicio de Nefrología (8ª Planta, Hospital General)
 Hospital Universitario La Paz
 Pº Castellana, 261.
 28046 Madrid. Spain
 E-mail: egonzalez_sp@hotmail.com.