

***De novo* hypertension and decline of renal function in a young woman with systemic lupus erythematosus and antiphospholipid syndrome**

Helena Viana, Aníbal Ferreira, Fernanda Carvalho, Joaquim Bordalo, João Ribeiro Santos

Serviço de Nefrologia, Hospital de Curry Cabral. Lisbon, Portugal.

Received for publication: 02/05/2009

Accepted in revised form: 17/08/2009

■ ABSTRACT

Antiphospholipid syndrome nephropathy and lupus nephritis have similar clinical and laboratory manifestations and achieving the accuracy of diagnosis required for correct treatment frequently necessitates a kidney biopsy.

We report the case of a 29-year-old woman referred to the nephrology service for *de novo* hypertension, decline of renal function and proteinuria. She had had systemic lupus erythematosus and antiphospholipid syndrome since the age of 21 and was taking oral anticoagulation. Two weeks later, after treatment of hypertension and achievement of adequate coagulation parameters, a percutaneous renal biopsy was performed. The biopsy revealed chronic lesions of focal cortical atrophy, arterial fibrous intimal hyperplasia and arterial thromboses, which are typical features of antiphospholipid syndrome nephropathy.

We describe the clinical manifestations and histopathology of antiphospholipid syndrome nephropathy and review the literature on renal biopsy in patients receiving anticoagulation.

Key-Words:

Antiphospholipid syndrome; hypertension; kidney biopsy; systemic lupus erythematosus.

■ INTRODUCTION

Although the renal manifestations of antiphospholipid syndrome (APS) have received scant attention until recently, the kidney is probably a major target organ in this syndrome. Antiphospholipid antibodies are detected in 30-40% of patients with systemic lupus erythematosus (SLE) and APS will develop in nearly one third of these patients¹. Moreover, the kidney is commonly involved in SLE, with 60-80% of patients developing urine or renal function abnormalities at some time during their clinical course².

APS nephropathy and lupus nephritis have similar clinical and laboratory manifestations and a kidney biopsy is frequently required for accurate diagnosis and correct treatment.

■ CASE REPORT

A 29-year-old woman was referred to the nephrology department for evaluation of declining renal function and proteinuria. Systemic lupus erythematosus (SLE) and antiphospholipid syndrome (APS) had been diagnosed at the age of 21 years old. The diagnosis of APS had been established after she had

developed a left lower leg deep venous thrombosis. The lupus disease had cutaneous, articular and psychiatric involvement, without known renal manifestations. Over the next 8 years she had been treated with warfarin (INR target: 2-3), prednisolone (10 mg/day) and hydroxychloroquine (200 mg/day). She had some cutaneous and articular lupus relapses needing temporary increases of prednisolone dose. There had been no further clinically evident thrombosis episodes. She had never been pregnant. Her records showed proteinuria (0.5 mg/24 hours) over the previous 2 years and an increase in serum creatinine from 0.9 to 1.3 mg/dl in the previous 3 months.

She presented to the nephrologist with *de novo* hypertension (150/110 mmHg), cutaneous lesions (butterfly malar rash, alopecia, livedo reticularis and purpuric vasculitis of fingers, toes and nail folds) and musculoskeletal manifestations (arthralgia and arthritis of finger and toe joints).

Investigations showed: 1) positive antinuclear, double stranded DNA, anti Ro/SSA antibodies; 2) slightly low complement fractions: C₃ (67.4 mg/dl; N: 75-140) and C₄ (9.50 mg/dl; N: 10-34); 3) positive antiphospholipid antibody: Anticardiolipin antibody (>120 units GPL; N<12), Anti-B₂ glycoprotein-I (>100 units SGU; N<12) and Lupus anticoagulant (1.65 R; N: 0.8-1.2); 4) slight reduction in size of the right kidney (10.1 cm vs 11.3 cm), with bilateral normal echogenicity, and regular contours.

The patient's anticoagulation status did not allow immediate kidney biopsy and she began mycophenolate mofetil (500 mg/day) and lisinopril (20 mg/day).

Two weeks later, warfarin was stopped and low molecular weight heparin (LMWH) introduced (interrupted 24 hours before biopsy). With normotension and adequate coagulation parameters (PT, PTT, platelet count, anti-Xa activity), a percutaneous renal biopsy was performed using a semi-automated device with real time ultrasonic guidance. In the absence of biopsy complication, LMWH was restarted after 48 hours, and warfarin one week later.

The kidney histology revealed a cortical specimen with 50 glomeruli: 25 glomeruli showed ischaemic

retraction of the tuft – some with a pseudocystic appearance (Fig. 1); 10 were globally sclerosed by ischaemia and 15 were normal. Focal zones of atrophy were present in the subcapsular area, where 5 of the 10 sclerosed glomeruli were seen, and in the deep cortex (Fig. 2). The ischaemic and sclerotic alterations described were mainly in these zones, where some infiltration by mononuclear inflammatory cells could be observed. Many vessels (arterioles and medium interlobular arteries) were patent but organised thrombi filled the lumens of 2 medium-

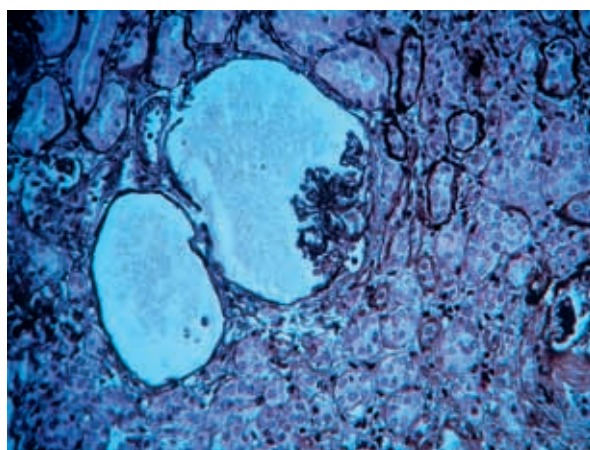


Figure 1

Retracted ischaemic glomerular tuft forming pseudocystic lesions. Magnification 250X, Silver stain.

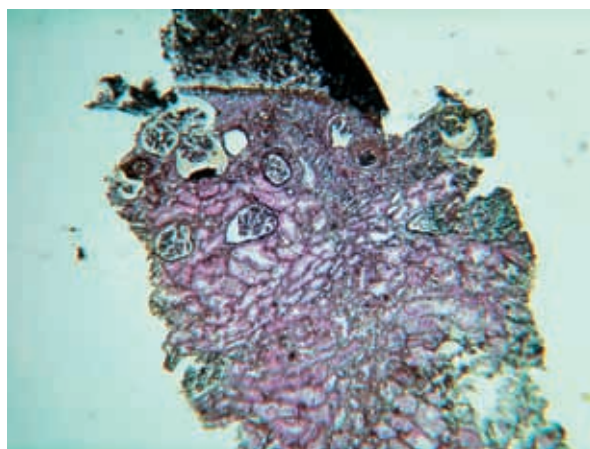


Figure 2

Focal cortical atrophy in subcapsular and deep cortical areas. Magnification 60X, Silver stain.

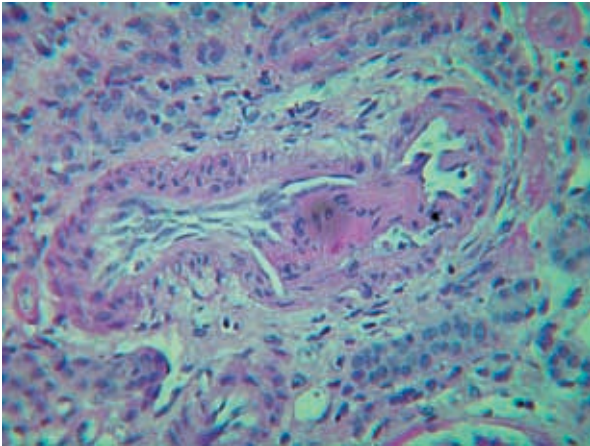


Figure 3
Fibrous organised thrombi and fibrous intimal hyperplasia in medium-calibre artery. Magnification 250X, Periodic acid-shiff stain.

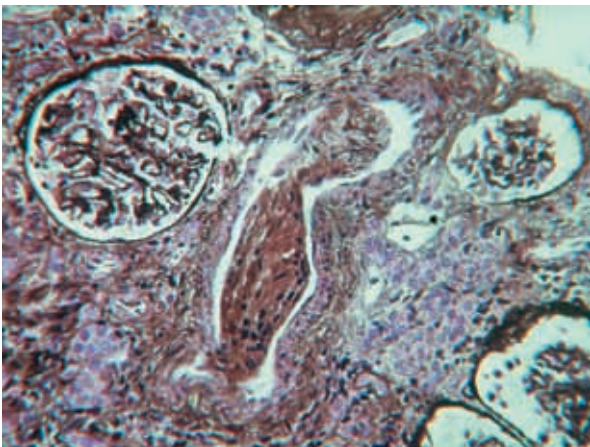


Figure 4
Fibrous thrombi filling lumen of medium-sized artery and ischaemic glomeruli. Magnification 160X, Silver stain.

sized vessels (Figures 3 and 4). Some intimal hyperplasia could be seen in 2 further vessels. Vascular lesions were located exclusively in atrophic and fibrotic areas. Immunofluorescence revealed 8 glomeruli with IgM segmental deposits (++/+++). There was no deposition of IgG, IgA, C3, C4, C1q and fibrin in the glomeruli or in other parenchymal structures. The histological diagnosis was APS nephropathy so the warfarin dose was increased to obtain an INR around 3.5 and immunosuppressive therapy was not changed.

At present, 6 months later, the patient is in clinical remission from lupus and has stable renal function.

■ DISCUSSION

The renal manifestations of APS result from thrombosis occurring at any location within the renal vasculature, that is, in the renal arterial trunk or branches, intraparenchymal arteries and arterioles, glomerular capillaries, and renal veins. APS nephropathy (APSN) describes the parenchymal renal lesions following intrarenal thrombosis. Proven intrarenal thromboses, once other conditions resulting in similar renal lesions are excluded, have recently been included in the Classification Criteria for APS³. Daugas and colleagues⁴ studied the frequency and clinical relevance of APSN in lupus patients. This retrospective study showed that APSN was present in 32% of the patients with SLE, in addition to, or independent of, lupus nephritis.

The more frequent clinical renal manifestations of APSN and lupus nephritis are proteinuria (ranging from mild to nephrotic), haematuria, hypertension (often severe) and acute or chronic renal insufficiency.

The literature reveals that patients with APSN have a high frequency of hypertension and elevated serum creatinine levels at the time of kidney biopsy⁵. Hypertension was one of the first major features described in association with livedo reticularis and APS⁶. Patients with APS complicated by hypertension should be vigorously investigated for an underlying renal lesion, especially in the presence of livedo reticularis⁷. Thus, renal involvement should be considered in any patient suffering from APS and hypertension, regardless of whether it is accompanied by renal insufficiency, proteinuria, or haematuria⁸. The pathophysiology of hypertension in the context of APS includes thrombosis/occlusion of the trunk of a renal artery leading to renovascular hypertension as well as stimulation of the renin-angiotensin-aldosterone system secondary to intrarenal vascular lesions⁹.

APSN is a vaso-occlusive process associated with acute intrarenal thromboses and chronic vascular

lesions. The acute manifestations are the result of thrombotic microangiopathy (TMA). However, chronic vascular changes of APSN are more frequent than acute events, but have received little attention until recently. They are characterised by arterial fibrous intimal hyperplasia (FIH), arteriosclerosis and organised thrombosis with or without recanalisation. The thrombosis progresses to fibrous occlusion of vessels and lead to focal cortical atrophy (FCA) in the region served by the involved vessels, often including subcapsular areas⁸. Progression of acute thrombotic lesions to chronic proliferative, obstructive and fibrotic forms may occur, as observed by Tektonidou and colleagues¹⁰.

Thrombosis of parenchymatous vessels results in focal ischaemia and/or necrosis with corresponding reduction in kidney size or areas of cortical infarction on ultrasound or DMSA scanning¹¹.

Our case demonstrates that accurate assessment of the relative contributions of APSN and lupus nephritis may only be possible with a renal biopsy. Histological examination is fundamental for diagnosis and therapeutic decision that is immunosuppression and/or anticoagulation, and the amount of each.

Ultrasound-guidance and the use of semi-automated devices have made renal biopsy safe and reliable¹².

However, in patients on chronic anticoagulation two main problems must be considered: the risk of thrombosis if treatment is stopped *versus* the risk of bleeding after biopsy if anticoagulation is maintained. APS patients are classified as high risk for thromboembolism, and are usually considered to require “bridging” anticoagulation¹³ if oral anticoagulation is stopped.

Presently, there is no good evidence, nor clear consensus, for the management of patients receiving long-term oral anticoagulant therapy who need renal biopsy. The available data refers to experience with patients submitted to surgery.

In the general population and in perioperative experience, the use of LMWH seems to be safer, more effective, simpler and less costly for short-term bridging therapy than unfractionated heparin¹⁴. However, if LMWH is used in patients with creatinine clearance < 40 ml/min, the anticoagulant effect of LMWH should be measured with an anti-factor Xa level 4 hours

after LMWH administration, with a targeted therapeutic anti-factor Xa level of 0.5-1.5 U/ml¹⁰.

Jaffer *et al.*¹³ counsel about general patients and in perioperative cases: 1) to stop warfarin 5 days before; 2) to start LMWH 36 hours after the last warfarin dose; 3) to give the last dose of LMWH approximately 24 hours before; 4) to restart LMWH 24 hours after the procedure if there is no contraindication; 5) to restart warfarin 24 hours later; 6) to discontinue LMWH when INR is 2-3 for 2 consecutive days.

In nephrology, the data are lacking and some nephrologists preferred unfractionated heparin for all patients or in cases of reduced renal function. The timing of warfarin restarting is also debatable.

In our experience, we use the following scheme with satisfactory results: 1) stop warfarin 5-7 days before renal biopsy; 2) introduced low molecular weight heparin (LMWH) when INR<2; 3) interrupt LMWH 24 hours before biopsy; 4) evaluate/correct coagulation parameters (PT, PTT, platelet count, anti-Xa activity) and haemoglobin level in biopsy day; 5) evaluate/optimize arterial pressure; 6) perform percutaneous renal biopsy using a semi-automated device with real time ultrasonic guidance; 7) restart LMWH after 48 hours in the absence of biopsy complication; 8) restart warfarin 5-7 days later.

The intensity of long-term oral anticoagulation required for APS patients has been debated¹⁵. Randomised controlled trials have suggested that INR levels of 2.0-3.0 may be sufficient in uncomplicated APS patients with only venous thrombotic events. In patients with arterial events or with recurrent thrombotic events despite INR in this range, the anticoagulation intensity should probably be increased, with a target INR between 3.0 and 4.0.

■ CONCLUSION

The clinical patterns of lupus nephritis and APSN are often similar. Biopsy is essential for an accurate diagnosis and institution of appropriate therapy. Even in anticoagulated patients, renal biopsy may be performed safely if appropriate peribopsy measures are taken.

Conflict of interest statement. None declared.

References

1. Love PE, Santoro SA. Antiphospholipid Antibodies: Anticardiolipin and the Lupus Anticoagulant in Systemic Lupus Erythematosus (SLE) and in Non-SLE Disorders. Prevalence and Clinical Significance. *Ann Intern Med* 1990;112:682-698
2. Cameron JS. Lupus Nephritis. *J Am Soc Nephrol* 1999;10:413-424.
3. Miyakis S, Lockshin MD, Atsumi T, *et al.* International consensus statement on an update of the classification criteria for definite antiphospholipid syndrome (APS). *J Thromb Haemost* 2006;4:295-306
4. Dugas E, Nochy D, Huong DT, *et al.* Antiphospholipid Syndrome Nephropathy in Systemic Lupus Erythematosus. *J Am Soc Nephrol* 2002;13:42-52
5. Tektonidou MG, Sotsiou F, Nakopoulou L, Vlachoyiannopoulos PG, Moutsopoulos HM. Antiphospholipid Syndrome Nephropathy in Patients With Systemic Lupus Erythematosus and Antiphospholipid Antibodies. Prevalence, Clinical Associations, and Long-Term Outcome. *Arthritis Rheum* 2004;50:2569-2579
6. Hughes, G.R. The Prosser-White oration 1983. Connective tissue disease and the skin. *Clin Exp Dermatol* 1984;9:535-544
7. Sangle, S, D'Cruz, D., Khamashta, M., Hughes, G.R.V. Prevalence of hypertension in 600 patients with antiphospholipid syndrome. *Rheumatology (Oxford)* 2004;43:105-110
8. Nochy D, Dugas E, Droz D, *et al.* The Intrarenal Vascular Lesions associated with Primary Antiphospholipid Syndrome. *J Am Soc Nephrol* 1999;10:507-518
9. Amigo MC. Kidney disease in Antiphospholipid Syndrome. *Rheum Dis Clin North Am* 2006;32:509-522
10. Tektonidou MG, Sotsiou f, Nakpoulou L, Vlachoyannopoulos PG, Moutsopoulos HM. Antiphospholipid Syndrome Nephropathy in Patients with Systemic Lupus Erythematosus and Antiphospholipid antibodies. *Arthritis and Rheumatism* 2004;8:2569-2579
11. Calhoun WB, Hartshorne MF, Servilla KS, Tzamaloukas AH. Renal cortical perfusion defects caused by antiphospholipid syndrome seen on fusion imaging. *Clin Nucl Med* 2003;28:853-854
12. Hergesell O, Felten H, Andrassy K, Kühn K, Ritz E. Safety of ultrasound-guided percutaneous renal biopsy-retrospective analysis of 1090 consecutive cases. *Nephrol Dial Transplant* 1998;13:975-977
13. Jaffer AK, Brotman DJ, Chukwumerije N. When patients on warfarin need surgery. *Cleveland Clin J Med* 2003;11:973-984
14. Douketis JD, Johnson JA, Turpie AG. Low-Molecular-Weight Heparin as Bridging Anticoagulation During Interruption of Warfarin. Assessment of a Standardized Perioperative Anticoagulation Regimen. *Arch Intern Med* 2004;164:1319-1326
15. Lim W, Crowther MA, Eikelboom JW. Management of Antiphospholipid Antibody Syndrome: A Systematic Review. *JAMA* 2006;295:1050-1057

Correspondence to:

Dr Helena Viana
Serviço de Nefrologia, Hospital de Curry Cabral
Rua da Beneficência, 8
1069-166 Lisboa. Portugal
viana.helena@gmail.com